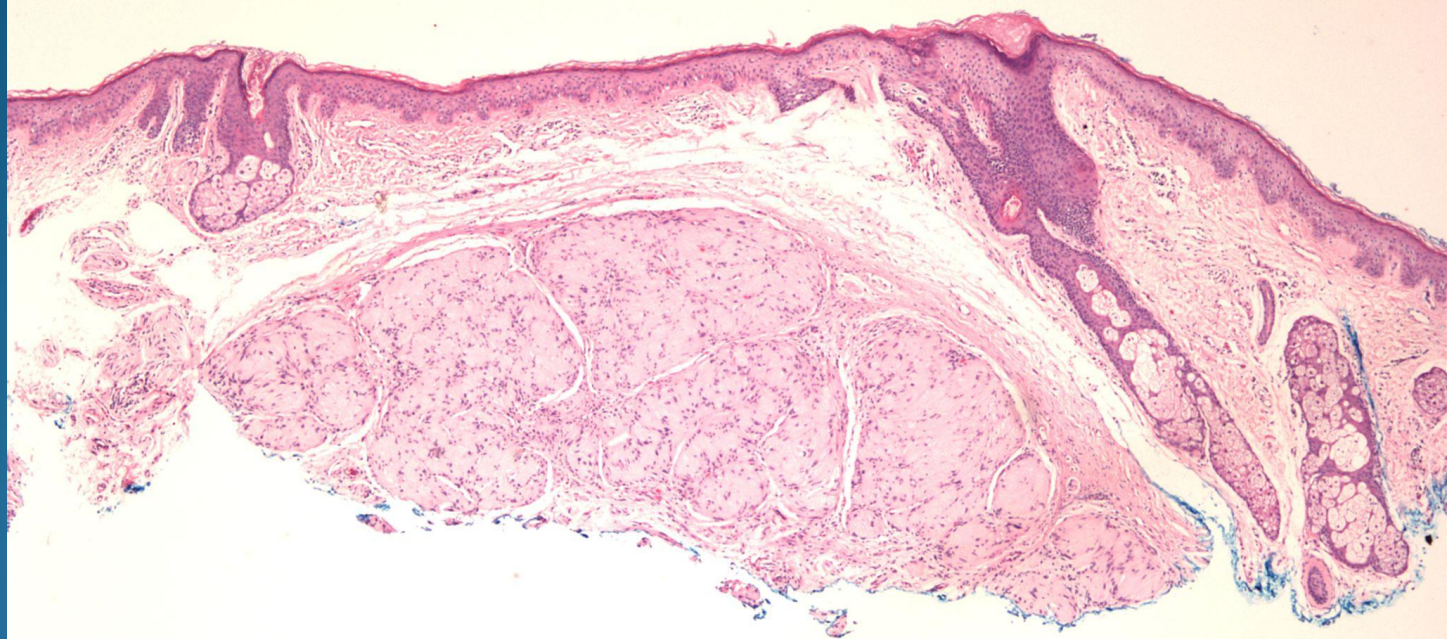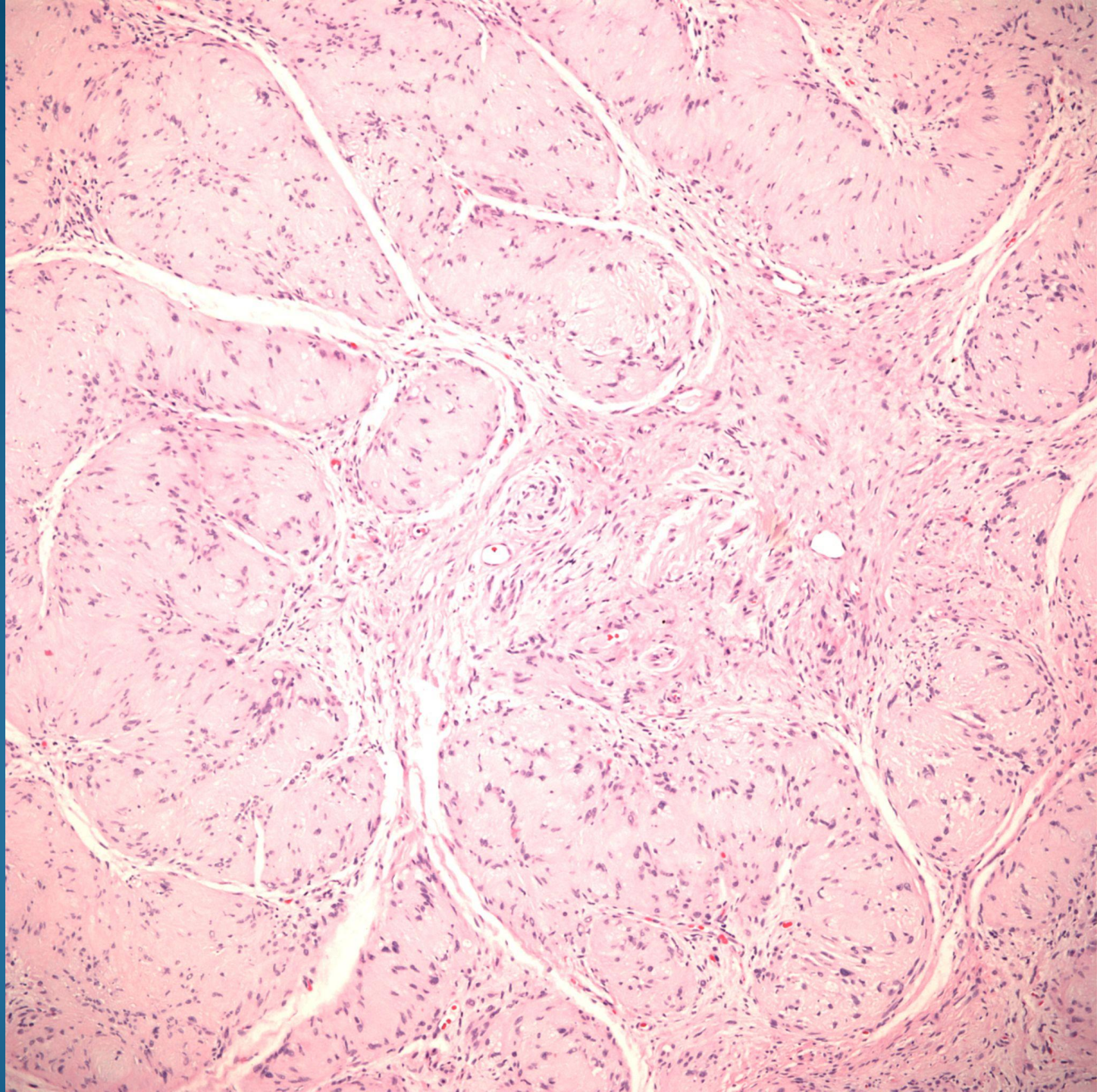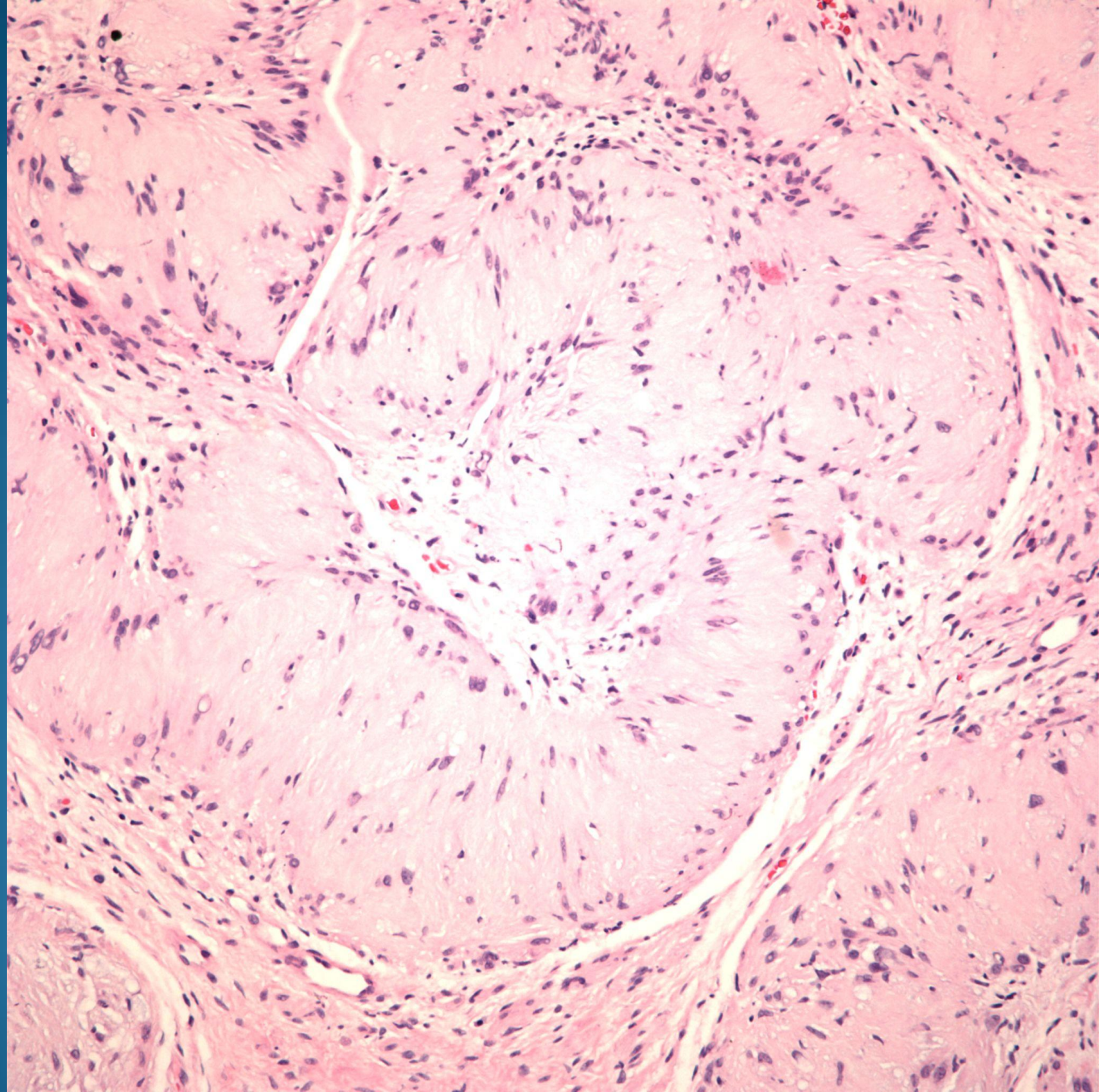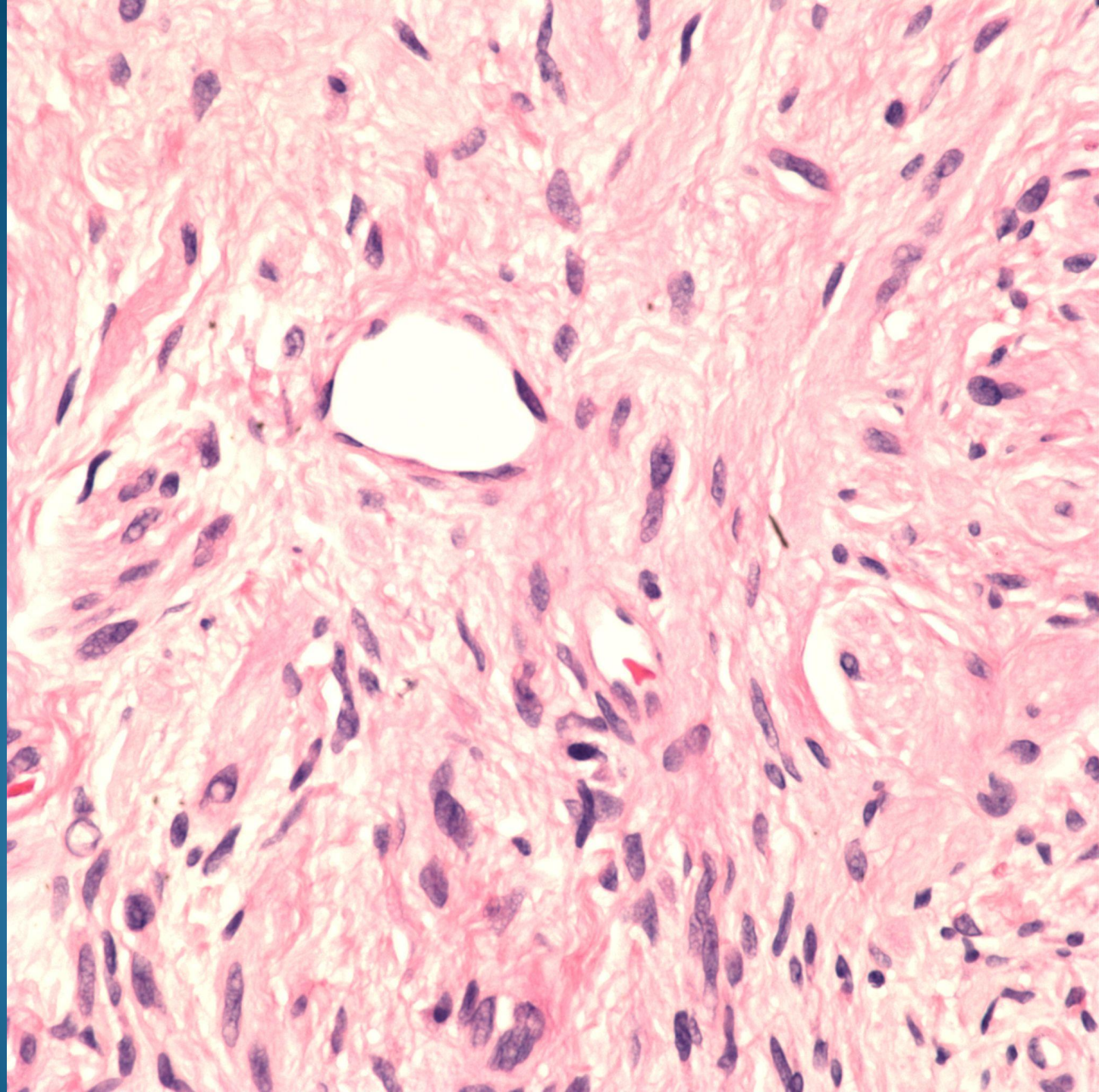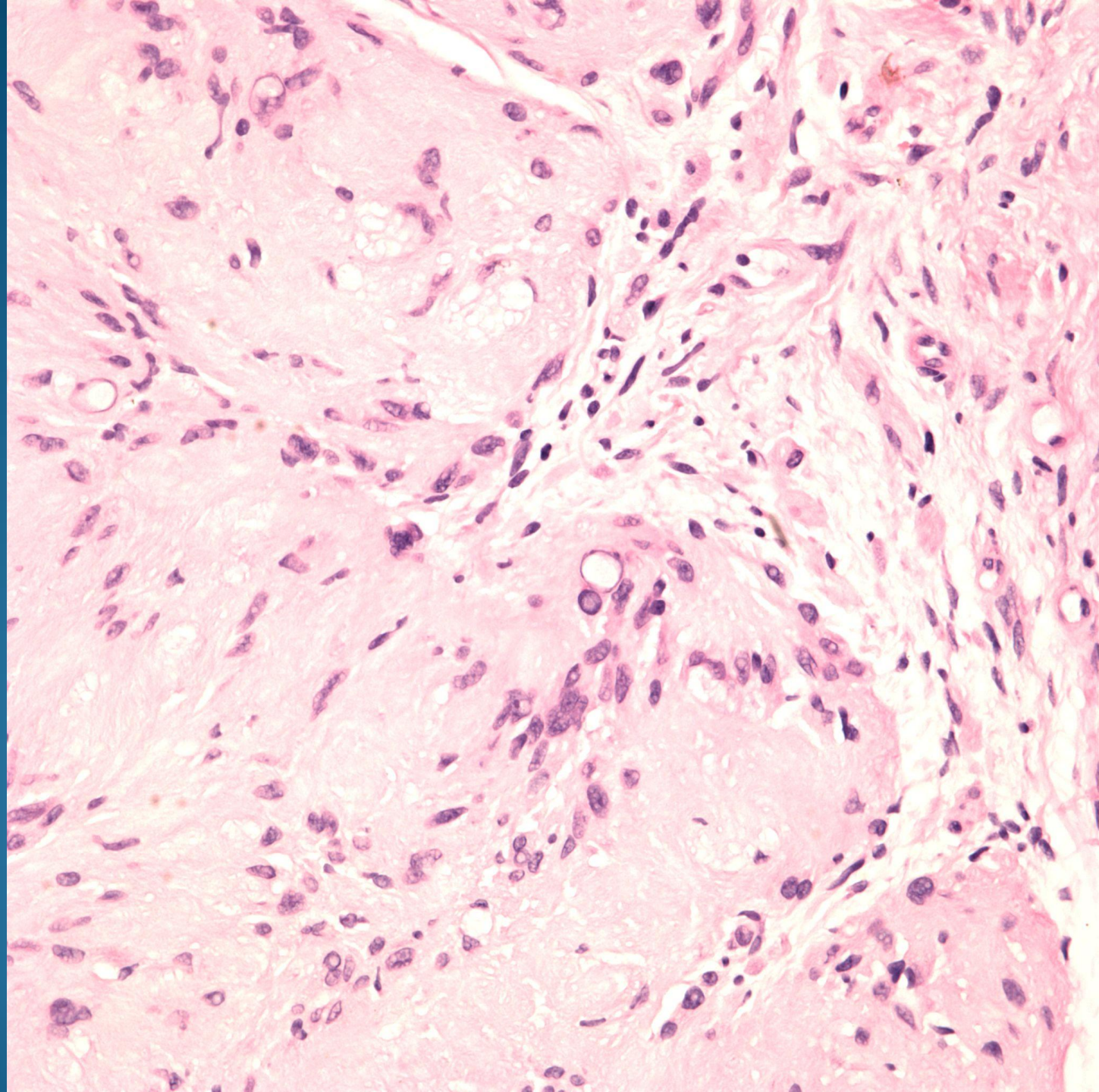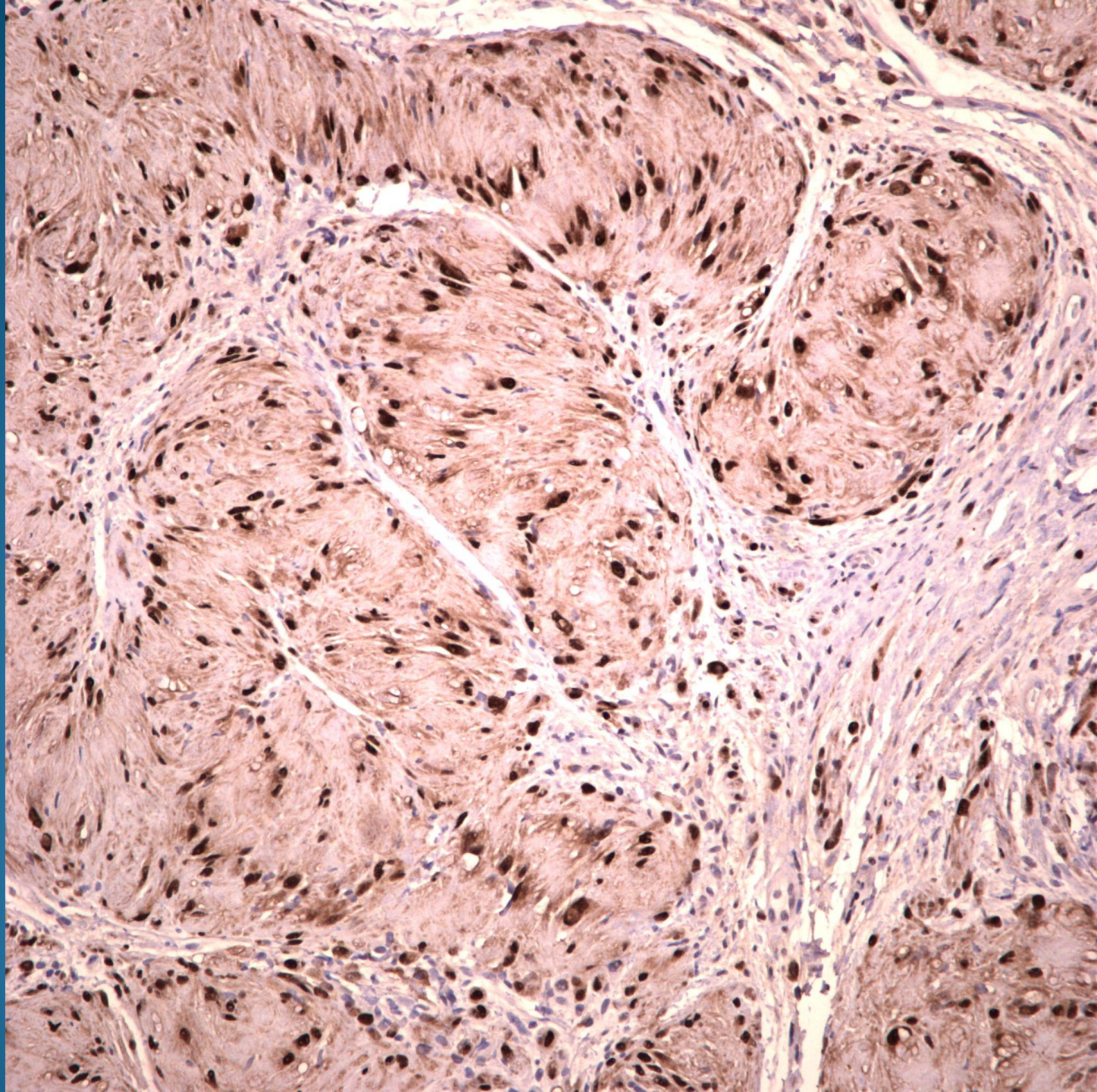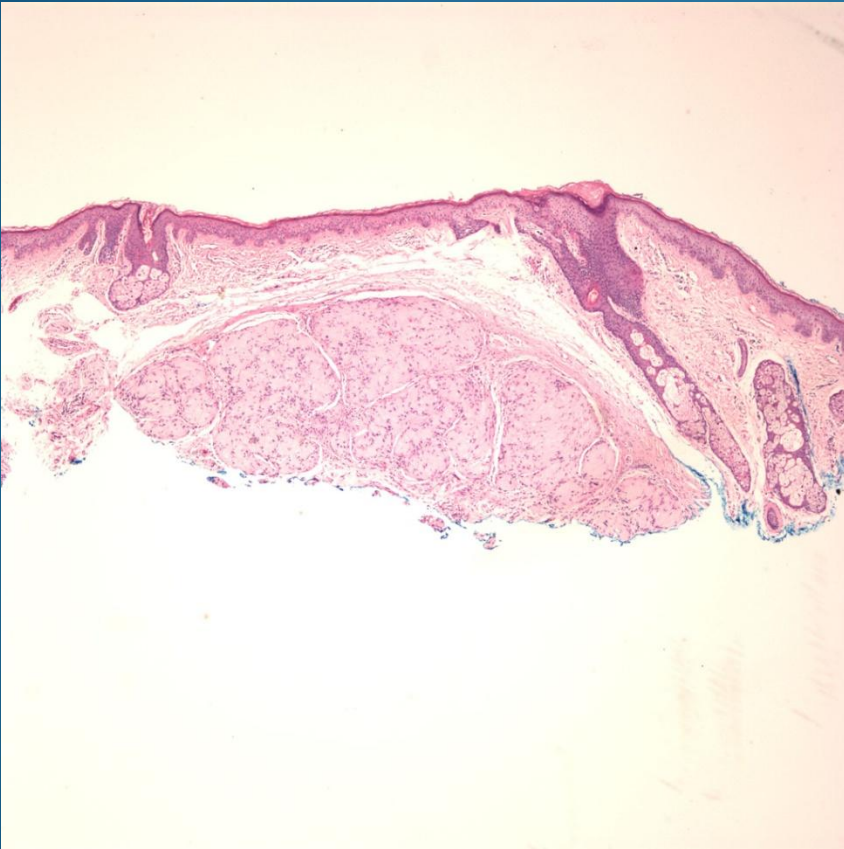


Cutaneous Schwannoma

Pearls



- Circumscribed dermal tumor
- Spindle cells with wavy nuclei
- May have Antoni A and B fibers
- Verroca bodies with vascular hyalinization
- Unusual variants with predominately Antoni A and Verroca bodies